

A Rare case of Paraplegia Following Transforaminal Epidural Steroid Injections with Dexamethasone

Anthony Karam DO, MS, Richesh Guragain MD, Moustafa Ahmed MD
Department of Anesthesiology, University of Texas McGovern School of Medicine

Introduction:

Lumbar transforaminal epidural steroid injections (TFESI) have been utilized to conservatively manage a number of spinal pain syndromes. These pain syndromes include disc herniation, spinal stenosis, failed back surgeries and many others. Radicular pain is caused by disc protrusion which leads to chemical and mechanical irritation of the nerve root. This results in inflammation and pain. The transforaminal approach is heavily utilized as it allows the maximum amount of steroid and local anesthetic to be delivered directly to the injured nerve root. The complications that can arise during lumbar TFESI are infection, hematoma, compromise of the intervertebral disc, intravascular injection of medication, exposure to radiation, hypersensitivity reaction due to medication, air embolism, urinary and bowel issues.

Most causes of paraplegia after lumbar TFESI are a direct result of accidental intravascular injection resulting in spinal cord infarction. In addition, in many of the reported incidents of paraplegia following a lumbar TFESI a particulate steroid was used ^{[1][2]}. Despite the potential catastrophic complications associated with lumbar TFESI, epidural steroid injections (ESI) are extremely safe. A recent retrospective study reviewing 53,000 patient records found the incidence of major complications of all ESIs performed at their institution to be 0.11% ^[3].

This case report presents a 48 year old female with baseline right sided lower extremity paralysis from a previous CVA. She received a three level lumbar TFESI with dexamethasone that resulted in left lower extremity paralysis within twenty four hours of injection. The exact etiology of the left lower paralysis is still unknown.

Materials and Methods:

All submission criteria were strictly observed. Patient informed consent was obtained for submission of this case report. All protected patient health information has been properly de-identified. This is a scientific abstract with no protected patient health information.

Case Description:

48 year old Female with a past medical history significant for a cerebrovascular accident complicated by right lower extremity paralysis and weakness of the right upper extremity, asthma and hypertension. Initially the patient presented with severe chronic lower back pain radiating to her left lower extremity in the distribution of L4, L5, and S1 dermatomes. The Patient denied having any left lower extremity weakness. Clinical examination was remarkable for positive straight leg test on the left. Lumbar Spine MRI showed findings significant for small central disc protrusion with posterior annular fissuring of L5-S1, minimal bilateral foraminal stenosis, minimal facet arthritic changes bilaterally, and extensive subcutaneous edema. The patient failed conservative therapy.

Patient was diagnosed with lumbar radicular pain syndrome due to leaky disc (chemical irritation). She was offered intervention left L4-L5, L5-S1, S1-S2 TFESIs. The procedure was

completed without an immediate complication utilizing a 5inch 22gauge Quincke needle, omnipaque 300 and with digital subtraction angiography. Once needle position was confirmed 2ml of (2ml of preservative free dexamethasone 10mg/ml and 4ml of bupivacaine 0.25%) was injected at each level indicated left L4-L5, L5-S1, S1-S2 levels. Twenty four hours after the procedure patient presented to the emergency room with left lower extremity paralysis. MRI and a CT scan of the lumbar spine were completed to rule out epidural hematoma and spinal cord infarction. Brain MRI and CT were performed and completed with no evidence of infarction or stroke. In addition, a neurologist and neurosurgery were obtained. It was determined that the patient may have an allergy to bupivacaine or dexamethasone. Currently the patient is still suffering from chronic neuropathic lower back pain and left lower extremity paralysis. She was recently successfully trialed for a spinal cord stimulator at T9 with over 70% pain relief. She is scheduled for Nevro HF10 implant.

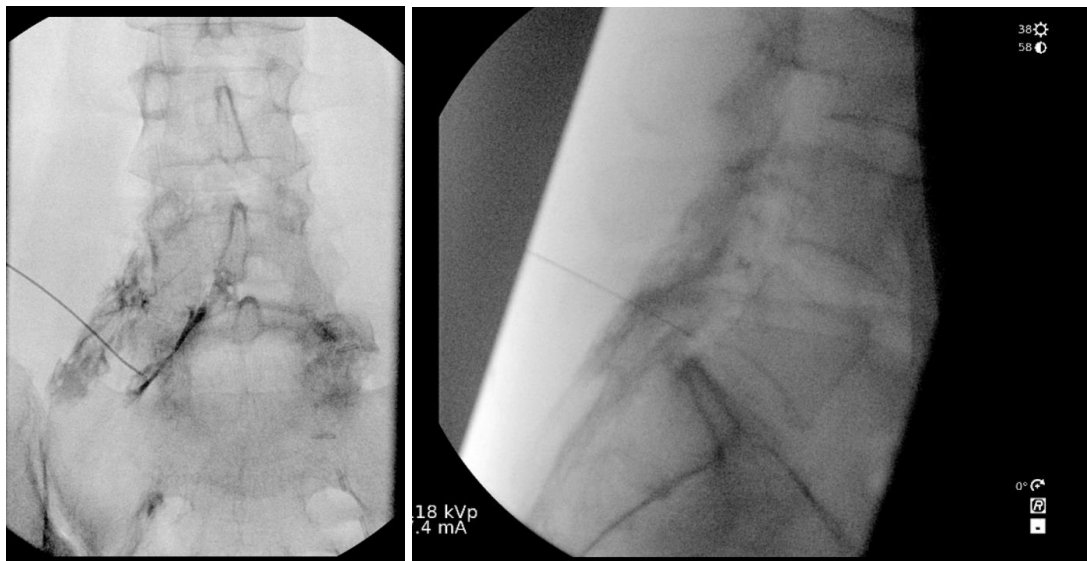

Figure 1: AP and Lateral Fluoroscopic Images of L5-S1 Intervertebral Foramen

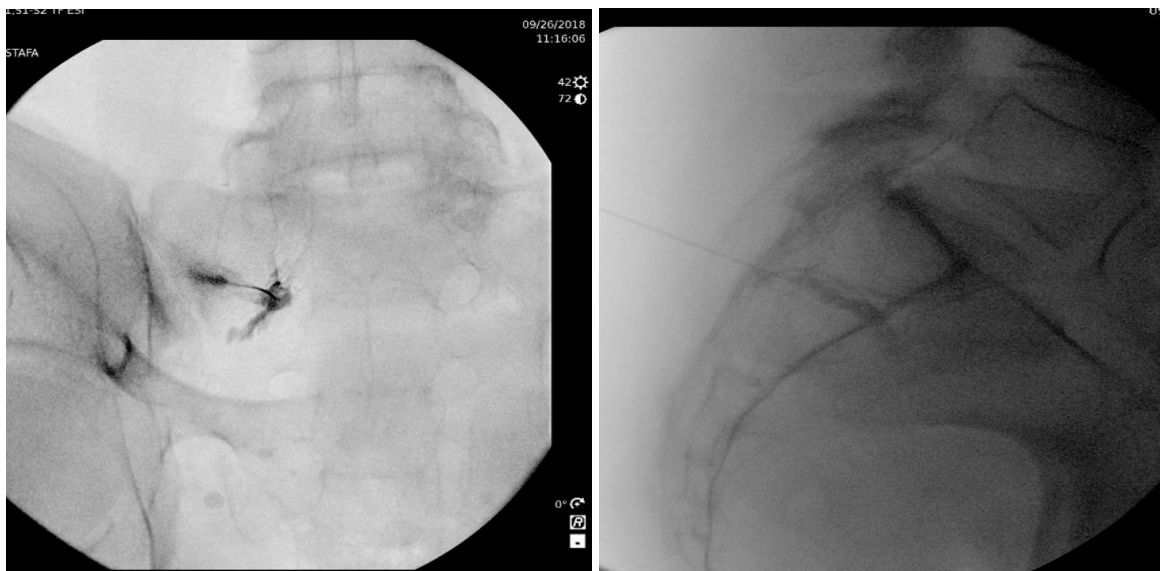


Figure 2: AP and Lateral Fluoroscopic Images of S1-S2 Intervertebral Foramen

Discussion:

The evidence of lumbar transforaminal epidural steroid injections for lumbar nerve root pain was strong for short-term and moderate for long-term improvement in two systematic reviews [4]. Complications of TFESI can be divided into two types: one related to needle placement and one related to drug administration [4]. Some common complications of TFESI includes dural puncture, infection, intravascular injection, air embolism, vascular trauma, particulate embolism, cerebral thrombosis, epidural hematoma, spinal cord damage, and complications related to administration of steroids [4].

There have been cases of paraplegia after TFESI described due to accidental intravascular injection of particulate and nonparticulate steroids resulting in vasospasm, thrombus formation, vessel dissection, and micro emboli [1][5]. In this case, fluoroscopic imaging was used to guide the needle into the epidural space (Figure 1 and 2). Digital subtraction angiography was utilized prior to drug administration at each level. This confirmed correct needle placement. MRI and CT of the lumbar spine performed twenty-four hours after procedure also suggested no signs of hematoma, signs of vascular injury, and spinal cord ischemia. Thus we can confidently conclude that complications related to needle placement resulting in vascular injury is highly unlikely in this case.

Another possible etiology for complications related to lumbar TFESI is due to drug administration. Multiple case reports have suggested that both particulate and nonparticulate steroids can be associated with spinal cord ischemia leading to paralysis [1]. It is important to note that the majority of catastrophic complications are due to injection of particulate steroids. In this case, the etiology of spinal cord injury resulting in new left lower extremity paralysis is likely related to drug administration. It is postulated that this patient may have had a hypersensitivity reaction to dexamethasone or bupivacaine.

Conclusion:

Lumbar transforaminal epidural steroid injections are an extremely safe intervention for the management of lumbar spinal pain syndromes. Minor and major adverse events are extremely rare when performed utilizing evidence based practice guidelines. Despite the current hypothesis of drug reaction secondary to bupivacaine and/or dexamethasone injection into the epidural space, the etiology of this patient's left lower extremity paralysis is still unknown.

References:

1. Gharibo C, Fakhry M, Diwan S, Kaye AD. Conus Medullaris Infarction After a right L4 transforaminal epidural steroid injection using dexamethasone. *Pain physician* 2016; 19:E1211-E1214

2. AbdeleRahman KT, Rakocevic G. Paraplegia Following Lumbosacral Steroid Epidural Injections. *Journal of Clinical Anesthesia*. 26. 10.1016/j.jclinane.2014.03.010
3. Lee JW, Lee E, Lee GY, Kang Y, Ahn JM, Kang HS. Epidural steroid injection-related events requiring hospitalisation or emergency room visits among 52,935 procedures performed at a single centre. *European Radiology*. 28. 10.1007/s00330-017-4977-7
4. Boswell MV, Trescott AM, Datta S, American Society of Interventional Pain Physicians et al. Interventional techniques: evidence-based practice guidelines in the management of chronic spinal pain. *Pain Physician*. 2007;10:7–111.
5. Wybier, M., Gaudart, S., Petrover, D. et al. *Eur Radiol* (2010) 20: 181. <https://doi.org/10.1007/s00330-009-1539-7>